

DO PEOPLE WITH UNILATERAL CAM FAI FAVOUR THEIR SYMPTOMATIC LEG DURING MAXIMAL DEPTH SQUATS?

Matthew J Kennedy¹, Mario Lamontagne^{1,2}, Paul E Beaulé³

School of Human Kinetics, University of Ottawa, ON, Canada¹
Department of Mechanical Engineering, University of Ottawa, ON, Canada²
Division of Orthopaedic Surgery, University of Ottawa, ON, Canada³

Cam Femoroacetabular Impingement (FAI) is caused by an abnormally convex femoral head-neck junction and can damage the peripheral acetabulum in activities requiring a large hip range of motion (ROM). This study analyzed the three-dimensional (3D) ground reaction forces (GRF) and moments (GRM) and the resultant GRF of the symptomatic and asymptomatic legs in participants with unilateral cam FAI during a maximal depth squat. Seventeen participants with unilateral cam FAI performed 5 maximal depth squats with each leg on a separate forceplate. No significant differences were found between the two legs. These results indicate that participants with cam FAI do not favour their affected leg during maximal depth squats.

KEY WORDS: Femoroacetabular impingement, Biomechanics, Squat, Kinetics

INTRODUCTION: FAI is a cause of hip pain in young active adults and is believed to cause osteoarthritis (OA) of the hip (Ganz et al., 2003; Wisniewski and Grogg, 2006). Up to 24% of highly athletic males may have cam FAI (Murray and Duncan, 1971) and elite athletes with FAI report decreased sport performance (Philippon et al., 2007). Cam FAI is caused by an abnormal bony ridge on the femoral head which is driven into the peripheral acetabulum at the limits of hip ROM (Ito et al., 2001). This repetitive contact particularly during rapid athletic movements can cause the articular cartilage to be sheared off the acetabular rim and can result in labral tears (Beck et al., 2005). The high prevalence of FAI in athletes and the serious damage it can cause make it imperative for us to increase our understanding of this deleterious condition.

Cam FAI causes hip pain in movements which require large hip flexion such as deep sitting, and athletic activities (Wisniewski and Grogg, 2006; Laude et al., 2007), and reduces hip function. Both peak hip ROM and maximal squat depth are reduced in participants with cam FAI as compared to healthy controls (Kennedy et al., 2009 (In Press); Lamontagne et al., 2009). Furthermore, Philippon et al. (2007) found that people with unilateral FAI have reduced passive hip ROM in the symptomatic leg compared to the contralateral leg. Maximal depth squat is a demanding but controlled movement requiring near maximal hip flexion angles in participants with FAI (Flanagan et al., 2003; Kennedy, 2009 (In Press)), making it a good movement to isolate biomechanical differences between symptomatic and asymptomatic legs in unilateral FAI. The purpose of this study was to determine whether or not participants diagnosed with unilateral cam FAI favour their symptomatic leg during strenuous closed chain activities such as maximal depth squats. We postulated that participants with unilateral cam FAI would have a larger resultant GRF in the asymptomatic leg compared to the symptomatic leg.

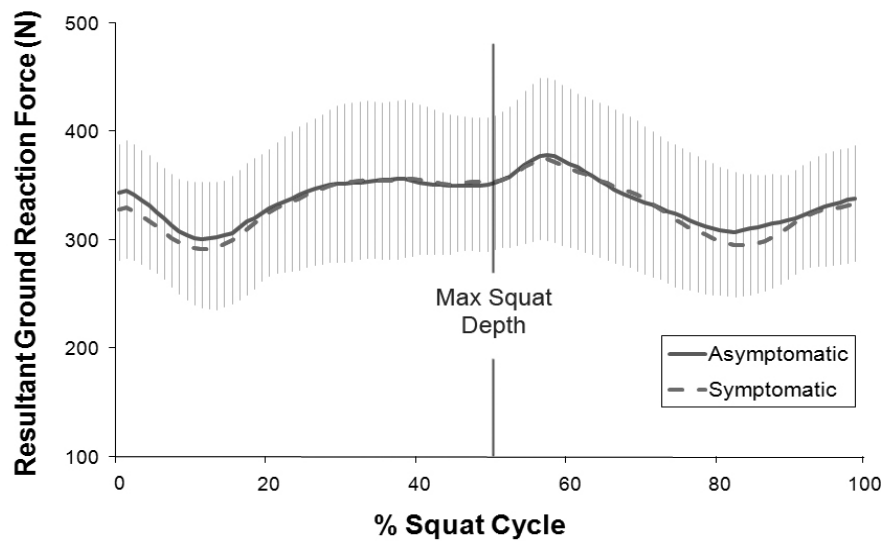


Figure 1. Maximal depth squat resultant ground reaction force between the asymptomatic and symptomatic legs of participants with unilateral cam FAI. A very similar peak resultant GRF was generated by the symptomatic and asymptomatic legs ($p = 0.786$)

METHODS: Data Collection: Seventeen participants (7 females; 10 males) diagnosed with unilateral cam FAI participated in this study. All participants were fit and otherwise healthy, with an average age of $35.5 (\pm 10.6)$ years, and average BMI of $23 (\pm 2.3)$ kg/m². Participants were all diagnosed by the same clinician (PB) having a positive impingement test, visible cam morphology and an α angle indicative of FAI as determined by radiographs. Participants were excluded if OA was visible on radiographs. All participants signed an informed consent approved by the Ottawa Hospital and the University of Ottawa Ethics Boards.

After a preliminary stretch and warm-up, participants performed five maximal depth squats with one foot on each of two forceplates (AMTI OR-6, Watertown, MA, USA). Participants stood with their feet shoulder-width apart, their arms extended anteriorly and maintained heel contact throughout the squat. Maximal squat depth was controlled by an adjustable bench set to 1/3 tibial height, and positioned behind the participant. Participants were instructed to squat as low as possible and to ascend back to standing while maintaining control. Maximal depth was attained by touching their buttocks to the bench.

Data Analysis: 3D GRF, GRM and the resultant GRF generated by the asymptomatic and symptomatic legs of each participant were measured for all five trials. These variables were then averaged across trails and ensemble averaged across participants and compared between the two legs using one-way between-group ANOVAs ($\alpha = 0.05$) for each dependent variable. A one-way between-group ANOVA ($\alpha = 0.05$) was also run comparing the resultant force between the dominant and non-dominant legs to ensure that leg dominance was not a confounding variable.

RESULTS: There were no significant differences found between the 3D GRFs, GRMs, or in the resultant GRF (Figure 1) between the asymptomatic and symptomatic legs.

The peak 3D GRFs and resultant GRF were very similar between the two legs, with p values ranging from 0.869 to 0.765 for the 3D GRFs, and 0.786 for the resultant GRF. There were also very little differences between the symptomatic and asymptomatic legs for the peak GRMs, with p values ranging from 0.995 to 0.389.

DISCUSSION: There have been no previous kinetic studies comparing symptomatic and asymptomatic legs in participants with unilateral FAI. However, as mentioned previously,

people with unilateral FAI have reduced hip ROM in their symptomatic hip compared to their asymptomatic hip (Philippon et al., 2007). Furthermore, people with FAI experience pain in their symptomatic hip(s) during deep sitting (Laude et al., 2007) – which is very similar to deep squats. Both of these findings indicate that people diagnosed with unilateral FAI have limitations in their symptomatic leg compared to their asymptomatic leg.

According to a study conducted in our lab using a similar population to this study, people with unilateral cam FAI cannot squat as low as matched controls. Only 33% of FAI participants could attain the lowest squat depth compared with 91% of the controls (Lamontagne et al., 2009). So few FAI participants being able to squat to the lowest depth indicates that squatting is a demanding activity for this population. Since participants with unilateral FAI have limited passive hip ROM in their symptomatic leg compared to their asymptomatic leg, and experience pain in deep sitting it seems logical that they would in turn favour this leg during strenuous activities requiring large hip mobility such as maximal depth squats. This however was not the case.

Surprisingly, in contradiction to our hypothesis unilateral FAI participants had no differences between the resultant GRF of their symptomatic and asymptomatic legs during maximal depth squats ($p = 0.786$). Furthermore there were no differences in any of the 3D GRFs or GRMs between the two legs. This indicates that this population does not favour their symptomatic leg during maximal depth squats.

One might assume that leg dominance could contribute to the kinetic symmetry between the symptomatic and asymptomatic legs. However Hesse et al. (1996) reported that although asymmetric weight distribution during sit-to-stand is common, it is not related to leg dominance. Furthermore, there was no significant difference in the resultant GRF between dominant and non-dominant legs ($p = 0.286$).

Based on the results from Lamontagne et al. (2009) which used a similar study population, the FAI group squatted using two different strategies, one with hip adduction and the other with hip abduction. This resulted in large kinematic variability in the frontal plane, which would likely be accompanied by large kinetic variability. Squat strategy was not restricted to ensure a natural movement representing participant's usual lower-limb kinetics. Although this may have masked differences in the individual GRFs and GRMs between the symptomatic and asymptomatic legs it would not affect the resultant GRF - our primary measure - since only its magnitude was compared between the two legs without considering the angle of application.

No differences were found in GRFs and GRMs during maximal depth squats indicating that participants with unilateral cam FAI generate the same net force in both legs during strenuous closed chain activities. Whether or not this uniform net GRF is generated using the same muscle contributions from each leg cannot be determined with certainty from this data, limiting its clinical relevance. However, the fact that the resultant GRF and all of the 3D GRF and GRM components were very similar between the two legs suggests similar joint kinetics. Although these are interesting novel results, it should be noted that these findings do not necessarily transfer to the rapid open chain and ballistic activities common in most sports.

CONCLUSION: Since FAI is a serious medical condition which primarily affects active adults and athletes, increasing our understanding of it is very important for sport scientists. Previous research has shown that FAI limits lower limb functionality and sports performance. Furthermore, in unilateral cases it has been shown that the symptomatic hip has a lower passive ROM compared to the asymptomatic hip. Although it was postulated that people with unilateral cam FAI would favour their symptomatic leg during maximal depth squats, this hypothesis was disproven. Unilateral cam FAI participants had very similar GRFs and GRMs between the symptomatic hip and the asymptomatic hip during maximal depth squats. This indicates that people with this condition do not favour their symptomatic hip during strenuous closed chain activities.

REFERENCES:

- Beck, M., Kalhor, M., Leunig, M., & Ganz, R. (2005). Hip morphology influences the pattern of damage to the acetabular cartilage: femoroacetabular impingement as a cause of early osteoarthritis of the hip. *The Journal of Bone and Joint Surgery*, *87*, 1012-1018.
- Flanagan, S., Salem, G. J., Wang, M. Y., Sanker, S. E., & Greendale, G. A. (2003). Squatting exercises in older adults: kinematic and kinetic comparisons. *Medicine and Science in Sports and Exercise*, *35*, 635-643.
- Ganz, R., Parvizi, J., Beck, M., Leunig, M., Notzli, H., & Siebenrock, K. A. (2003). Femoroacetabular impingement: a cause for osteoarthritis of the hip. *Clinical Orthopaedics and Related Research*, 112-120.
- Hesse, S., Schauer, M., Jahnke, M. (1996). Standing up in healthy subjects: symmetry of weight distribution and lateral displacement of the centre of mass as related to limb dominance. *Gait & Posture*, *4*, 287-292.
- Ito, K., Minka, M. A., 2nd, Leunig, M., Werlen, S., & Ganz, R. (2001). Femoroacetabular impingement and the cam-effect. A MRI-based quantitative anatomical study of the femoral head-neck offset. *The Journal of Bone and Joint Surgery*, *83*, 171-176.
- Kennedy, M., Lamontagne, M., Beaulé, P. E. (2009 (In Press)). The Effect of Cam Femoroacetabular Impingement on Hip Maximal Dynamic Range of Motion. *Journal of Orthopedics*.
- Lamontagne, M., Kennedy, M. J., & Beaulé, P. E. (2009). The effect of cam FAI on hip and pelvic motion during maximum squat. *Clinical Orthopaedics and Related Research*, *467*, 645-650.
- Laude, F., Boyer, T., & Nogier, A. (2007). Anterior femoroacetabular impingement. *Joint Bone Spine*, *74*, 127-132.
- Murray, R. O., & Duncan, C. (1971). Athletic activity in adolescence as an etiological factor in degenerative hip disease. *The Journal of Bone and Joint Surgery*, *53*, 406-419.
- Philippon, M., Schenker, M., Briggs, K., & Kuppersmith, D. (2007). Femoroacetabular impingement in 45 professional athletes: associated pathologies and return to sport following arthroscopic decompression. *Knee Surgery, Sports Traumatology, Arthroscopy*, *15*, 908-914.
- Philippon, M. J., Maxwell, R. B., Johnston, T. L., Schenker, M., & Briggs, K. K. (2007). Clinical presentation of femoroacetabular impingement. *Knee Surgery, Sports Traumatology, Arthroscopy*, *15*, 1041-1047.
- Wisniewski, S. J., & Grogg, B. (2006). Femoroacetabular impingement: an overlooked cause of hip pain. *American journal of physical medicine & rehabilitation / Association of Academic Physiatrists*, *85*, 546-549.